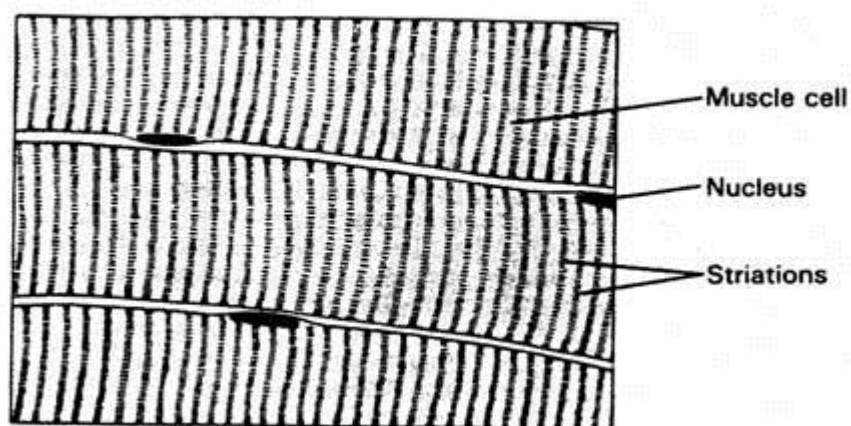


Muscle tissue

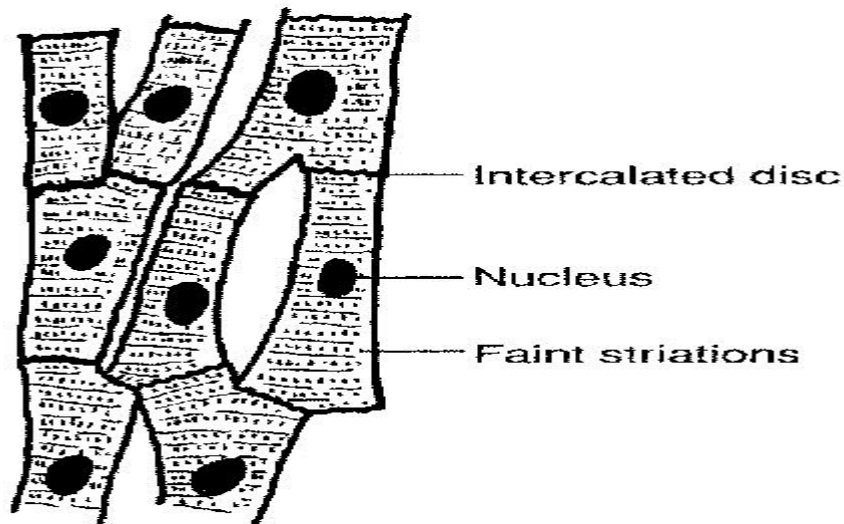
Muscle tissue is the fourth basic tissue type with epithelium , connective & nervous tissue. Is composed of cells that have contraction property, in all cells actin and myosin microfilaments. All muscle cells are of mesodermal origin . Three types of muscle tissue can be distinguished on the basis of morphologic and functional characteristics:

1-Skeletal muscle is a form of striated muscle tissue which is under the control of the somatic nervous system; that it is voluntarily controlled, most skeletal muscles are attached to bones by bundles of collagen fibers Skeletal muscle is made up of individual components known as myocytes, or "muscle cells", sometimes called "muscle fibers". They are formed from the fusion of developmental myoblasts (a type of embryonic progenitor cell that gives rise to a muscle cell) in a process known as myogenesis. These myocyte long, cylindrical, multinucleated peripherally (elongated nuclei) cells are also called myofibers.



2-Cardiac muscle is characterized by striped cylindrical muscle fibers, have central nuclei, connected together by **intercolated disks** (**Characteristics Features**), where the membranes are specialized to allow electrical signals to pass easily. **Cardiac Muscle Tissue found**

in (**Heart**), shows some of the characteristics of smooth muscle and some of skeletal muscle tissue. Its fibres , like those of skeletal muscle, have cross-striations and contain numerous nuclei. However, like smooth muscle tissue, it is involuntary.



3-Smooth muscle is an involuntary non-striated muscle. Smooth muscle is found within the walls of blood vessels .Smooth muscle is also found in lymphatic vessels, the urinary bladder, uterus, reproductive tracts, gastrointestinal tract, respiratory tract, It is spindle-shaped, central nuclei at widest part of cell. It is involuntary.

